

The Fistula Adapter - an Evolving Device in Treatment of Enteroatmospheric Fistulae

Olof Jannasch, MD*, Costanza Chiapponi, MD, Jörg Tautenhahn, PhD,
Christiane J. Bruns, PhD

Abstract — Negative pressure wound therapy is established in the management of the open abdomen but displays major problems in case of an accompanying intestinal fistula. Here we present a novel device for standardized treatment of enteroatmospheric fistulae - the fistula adapter.

Keywords — enteroatmospheric fistula, intestinal fistula, negative pressure wound therapy, open abdomen, vacuum therapy.



Fig. 1. Four available versions of the PPM-fistula adapter™-set (Fa. Phametra, Pharma & Medica-Trading GmbH, Herne/Ruhrstadt, Germany)

I. INTRODUCTION

THE introduction of negative pressure wound therapy (NPWT) has improved the treatment of an open abdomen in many ways.^{1,2,3} However, enteroatmospheric fistulae (EAF) remain a serious problem. NPWT, applied via foam to the wound surface, often leads to enlargement of the fistula or excrescence of the bowel mucosa. Additionally, viscous stool might obstruct the foam. This results in a separation of the foam from the wound surface. The suction starts to leak and this may lead to contamination or infection of the wound. Several drain-out systems using NPWT have been published.^{4,5} Unfortunately none of them could completely solve this problem. In most cases individual, time-consuming modifications of the wound dressing are necessary to avoid fistulas and obstruction of NPWT devices. In a first publication in 2011 we introduced the fistula adapter (FA) for treatment of EAF.⁶ Since then three new modifications have been developed to overcome some of the experienced problems. In this work we introduce these strategies.



Fig. 2. Two fistula adapters inserted in a foam, the lower brim is cut to match the outline of the foam

II. TECHNICAL DESCRIPTION

The FA consists of a soft thermoplastic elastomer to prevent pressure on the underlying wound surface. The original version had an inner diameter of 1.5 cm and a height of 3 cm (adjusted to commercially available polyurethane foams). A lower brim serves as interface to the wound surface and the upper brim as connection to an ostomy bag. Because of limitations with the original FA there are now four versions available (fig. 1).

Indication for use of the FA is a stage 4 open abdomen (frozen abdomen) with an enteroatmospheric fistula. In selected cases use in stage 3 open abdomen might also be indicated.⁷ Treatment goal is the healing of the wound area surrounding the EAF. This enables conventional ostomy therapy and discharge of the patient for further outpatient treatment. 6-12 month later a surgical resection of the fistula and final closure of the abdomen might be attempted.

Submitted on 20.06.2014.

Department of General, Abdominal and Vascular Surgery, University Hospital, Leipziger Str. 44, D-39120 Magdeburg, Germany, (OJ, CC, CJB); Department of Vascular Surgery, Municipal Hospital Magdeburg gGmbH, Birkenallee 34, D-39130 Magdeburg, (JT).

*Correspondence to Olof Jannasch Department of General, Abdominal and Vascular Surgery, University Hospital, Leipziger Strasse 44, D-39120 Magdeburg, Germany; phone: +49 391 67 15500, fax: +49 391 67 15570, email: olof.jannasch@med.ovgu.de

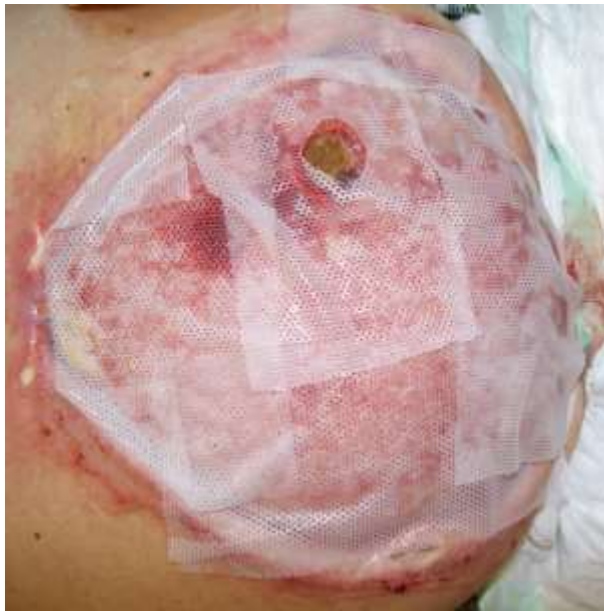

Fig. 3 Silicon gauze covering the wound surface with exception of the fistula

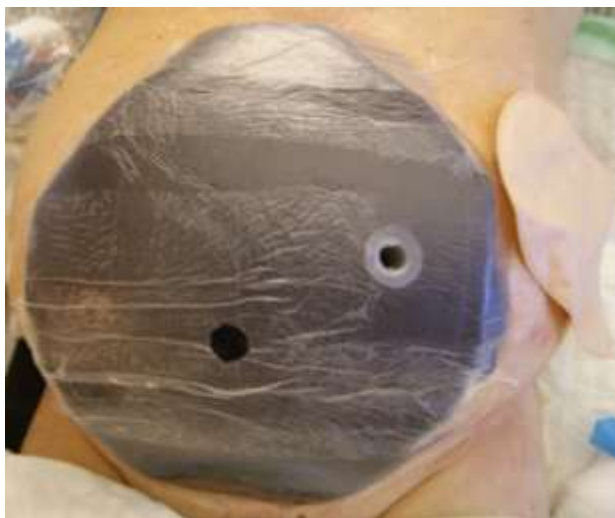


Fig. 4. Same patient as in Fig. 3, but foam and fistula adapter fixed by foil

After measurement of the fistula and of the wound size, a polyurethane foam is cut to match the wound surface. The opening in the foam for insertion of the FA can be made by using scissors or scalpel. The foam is easily manageable, so remaining parts can be stripped away without much effort. Then the adapter is inserted into the preformed hole in the foam. The hole should be a little smaller than the FA. If the adapter will be deformed after insertion, it can be easily reshaped by a little pressure. The fistula might be positioned next to the wound edge. The lower brim tends to overlap in this case. We usually cut it with the scissors to match the outline of the foam. Also more than one FA can be used in a foam (fig. 2). Next a silicone gauze will be aligned to the wound surface. In this way direct contact of the foam with the wound surface is prevented (fig. 3). Now the foam is placed. The FA has to enclose the underlying fistula. Afterwards the prepared foils are

affixed to keep foam and FA in place. It is best practice to remove the coverfilm from the foil and put the middle of the foil onto the fistula adapter. Then the foil is carefully fixed laterally. Next a hole for the suction pad is cut into the foil (fig. 4).

In case of a small wound area the suction pad cannot be placed directly beside the ostomy base plate. We therefore build a so called air-bridge. In this area the foil is already covering the skin, so there is no direct contact between foam and skin. This second small foam also has to be covered by a foil (fig. 5-7).



Fig. 5. Small foam for an air-bridge



Fig. 6. Fixed suction pad

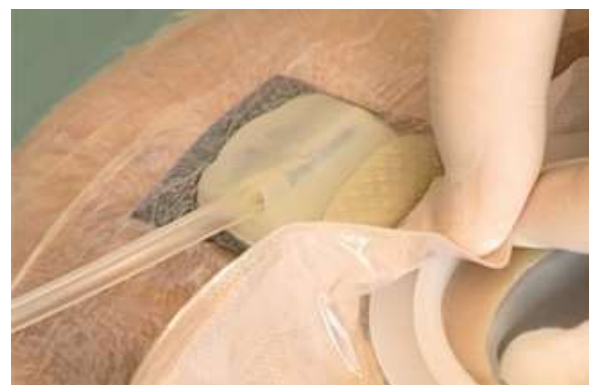

Fig. 7. Fixed ostomy bag after activating negative pressure wound therapy



Fig. 8. Complete dressing after activation of negative pressure wound therapy




Fig. 9. Test for leak tightness with an opened two-pieces appliance - the foam remains contracted

In a next step the suction pad is fixed. Afterwards the appliance can be put above the adapter after incision of the foil covering the FA. Then NPWT is activated. By this the FA is reliably fixed to the wound surface (fig. 8). According to the wound conditions a negative pressure of 75 to 125 mmHg should be used. To check the wound dressing we first look at the foam. It has to be contracted at all areas. To functionally control leak tightness we open the two-pieces appliance. If the foam remains contracted, we have proven leak tightness of the system (fig. 9). If the ostomy bag is filled with fluid or stool it can be emptied at any time or continuously via drain (fig. 10).



Fig. 10. Ostomy bag filled with stools while the foam remains clean

III. CONCLUSION

Here a novel device for managing EAF in a frozen abdomen using NPWT is presented. In most cases stable separation of the fistula from the negative pressure acting on the surrounding wound is achieved. The system can be easily applied and supports early mobilization of the patient as well as split thickness skin grafting. Most patients can be discharged for outpatient treatment with a conventional ostomy bag and, if desired, surgical revision 6-12 month later. With help of the newly developed versions of the FA some of the remaining problems could be solved. These are:

- large fistulae up to 4cm in diameter
- multiple fistulae lying next to another
- high output-volume fistulae
- colonic fistulae with formed stools
- deep positioned fistulae

For the problem of fistulae directly located at the wound margin an additional version of the FA is being developed.

REFERENCES:

- [1] Pieter Boele van Hensbroek, Jan Wind, Marcel GW Dijkgraaf, Olivier RC Busch, and J Carel Goslings. Temporary closure of the open abdomen: a systematic review on delayed primary fascial closure in patients with an open abdomen. *World journal of surgery*, 33(2):199–207, 2009.
- [2] R Weidenhagen, KU Gruetzner, R Kopp, FW Spelsberg, and KW Jauch. [role of vacuum therapy in the management of the septic abdomen]. *Zentralblatt für Chirurgie*, 131:S115–9, 2006.
- [3] Wild T, Stortecky S, Stremitzer S et al. [Abdominal dressing -- a new standard in therapy of the open abdomen following secondary peritonitis?]. *Zentralbl Chir*. 2006; 131: 111-114.
- [4] Goverman J, Yelon JA, Platz JJ et al. The “Fistula VAC”, a technique for management of enterocutaneous fistulae arising within the open abdomen: Report of 5 cases. *J Trauma*. 2006; 60: 428-431.
- [5] Layton B, Dubose J, Nichols S et al. Pacifying the open abdomen with concomitant intestinal fistula: a novel approach. *Am J Surg*. 2010; 199: e48-e50.
- [6] Jannasch O, Lippert H, Tautenhahn J. [A novel device for treating enteroatmospheric fistulae in the open abdomen]. *Zentralbl Chir*. 2011; 136(6): 585-589.
- [7] Martin Björck, Andreas Bruhin, Michael Cheatham, Daniel Hinck, Mark Kaplan, Guiseppe Manca, Thomas Wild, and Alastair Windsor. Classification—important step to improve management of patients with an open abdomen *World journal of surgery*, 33(6):1154–1157, 2009.